

Intraosseous Urography Compared with Intravenous Urography: An Experimental Study in the Rabbit Model

Mutlu SAĞLAM*, Şahin UĞUREL

Department of Radiology, Gülhane Military Medical Academy, 06018, Ankara - TURKEY

Mete KİLCİLER

Department of Urology, Gülhane Military Medical Academy, 06018, Ankara - TURKEY

Mehmet DAKAK

Department of Thoracic Surgery, Gülhane Military Medical Academy, 06018, Ankara - TURKEY

Ali BUMİN

Department of Radiology, Faculty of Veterinary Medicine, University of Ankara, 06110, Ankara - TURKEY

İbrahim SOMUNCU

Department of Radiology, Gülhane Military Medical Academy, 06018, Ankara - TURKEY

Received: 12.05.2003

Abstract: This study was performed to evaluate the feasibility of bone injection gun assisted intraosseous administration of contrast media as an alternative to the intravenous route for urography. Intravenous urographies were obtained in 6 rabbits. Urographic examinations by the intraosseous route were performed in the same animals 48 h later. After adequate anesthesia, the retroauricular vein was punctured for intravenous injection and a bone injection gun was used for intraosseous injections to the distal one-third of the rabbit femur. Direct radiographies of rabbits were obtained following 1200 mg/kg body weight iomeprol (300 mg iodine/ml) administration by both the intravenous and intraosseous routes at 5, 10, and 15 min. Although there was no prominent quality difference among the radiographs obtained by each route at 10 and 15 min, the 5 min radiograph of intraosseous urography showed the calyces more clearly compared to radiographs by intravenous urography. This was attributed to longer lasting high concentrations of iodine in the rabbit circulation after intraosseous injection owing to a longer injection time (mean 240 s) compared to the intravenous route (mean 35 s). Chest radiography and computed tomographic examinations did not reveal any sign of embolus. Bone radiography and magnetic resonance images were also free of any bone or bone marrow complications 48 h after intraosseous application. The success rate for adequate intraosseous insertion by bone injection gun was 100% in all 6 rabbits without any complications. In this study, urographic imaging via bone injection gun assisted intraosseous contrast administration seems to be safe and feasible in rabbits. As a result, we think that bone injection gun assisted intraosseous urography may be an effective and reliable alternative to intravenous urography in pediatric and adult human patients (especially those with ureteral trauma), when emergency urographic examination is necessary and the intraosseous route is the only means of vascular access.

Key Words: Intraosseous urography, intravenous urography, rabbit.

İntraosseöz Ürografinin İntrevenöz Ürografi ile Karşılaştırılması: Tavşan Modelinde Deneysel Bir Çalışma

Özet: Bu çalışma, ürografi elde edilmesinde kontrast maddenin intravenöz yola alternatif olarak "kemik enjeksiyon tabancası" yardımı ile intraosseöz verilmesinin uygulanabilirliğini değerlendirmek için yapıldı. 6 tavşanda intravenöz ürografiler elde edildi. 48 saat sonra aynı hayvanlarda intraosseöz yolla ürografik incelemeler yapıldı. Yeterli anesteziden sonra, intravenöz enjeksiyon için retroauriküler ven kullanıldı ve intraosseöz enjeksiyonlar için bone injection gun, tavşan femurunun 1/3 distaline uygulandı. 1200 mg/kg iomeprolin (300 mg iodine/ml) intravenöz ve intraosseöz yolla verilmesini takiben 5., 10. ve 15. dakikalarda tavşanların direkt radyogramları elde edildi. Kontrast maddenin intravenöz veya intraosseöz yolla verilmesinden elde edilen 10. ve 15. dakikada alınan ürogramların üriner sistem opasifikasyonlarında belirgin bir fark olmamasına rağmen 5. dakikada alınan intraosseöz ürografilerde kalikslerin, 5. dakikada alınan intravenöz ürografilere göre biraz daha net olduğu gözlemlendi. Bunun nedeninin kontrast maddenin intraosseöz (kontrast madde verilmiş zamanı: ortalama 240 saniye) yolla intravenöz (kontrast madde verilmiş zamanı: ortalama 35 saniye) yola göre

*Correspondence to: saglamm@gata.edu.tr

daha yavaş verildiği için sistemik dolaşımında daha fazla kontrast madde olmasından kaynaklanabileceği düşünüldü. Akciğer radyografisi ve bilgisayarlı tomografi incelemelerinde emboliye ait herhangi bir bulgu görülmedi. Ayrıca, intraosseöz uygulamadan 48 saat sonra herhangi bir kemik iliği komplikasyonu için kemik radyografisi ve manyetik rezonans görüntülemeleri de temiz idi. Kemik enjeksiyon tabancasının uygun intraosseöz yerleştirilmesi durumunda başarı oranı herhangi bir komplikasyon olmaksızın 6 tavsanda % 100 idi. Bu çalışmada, intraosseöz kontrast maddenin kemik enjeksiyon tabancası ile verilmesi sonucunda elde edilen ürografik görüntülemenin tavşanlarda güvenli ve kolay olduğu görülmektedir. Sonuç olarak, acil ürografik incelemenin gerekli olduğu ve intraosseöz yolun tek alternatif olduğu çocuk ve yetişkin hastalarda (özellikle üreteral travmalı) kemik enjeksiyon tabancası ile yapılan intraosseöz ürografinin intravenöz ürografiye karşı etkili ve güvenilir bir alternatif olabileceği düşünülmektedir.

Anahtar Sözcükler: İntraosseöz ürografi, intravenöz ürografi, tavşan.

Introduction

Intravenous urography (IVU) is the basic radiologic method for evaluating disorders of the urinary system (1). Ultrasonography (US), computed tomography (CT) and magnetic resonance imaging (MRI) play complementary roles in diagnosis (2-4). Direct visualization of the injury is the best and most accurate diagnostic modality in ureteral trauma. Delays in diagnosis of ureteral trauma have been associated with significant morbidity (5). Ureteral trauma is diagnosed by IVU, although contrast-enhanced CT urography and contrast-enhanced magnetic resonance (MR) urography may serve as helpful secondary tools (3,4,6). Half-Fourier acquisition single-shot turbo spin-echo (HASTE) MR urography can be used for imaging a dilated urinary tract. However, complete transection of the ureter with no filling of the ipsilateral ureter cannot be imaged with HASTE MR urography (7).

Despite improvements in techniques and equipment for obtaining venous access, it is not always possible to achieve a secure peripheral or central intravenous (IV) line as desired. This is especially important for pediatric patients known to have small vasculature, which is even more difficult to access at the time of vascular collapse associated with shock, soft tissue trauma, burns, cutaneous and subcutaneous edema, vascular thrombosis, and anatomical variations. For these reasons, an alternative route of delivering contrast media to patients in such situations is desirable. Although the intraosseous (IO) route was reported as an alternative way to administer fluids and drugs, its complications and limitations were also mentioned in the same reports (8-11).

For both IV and IO studies, all rabbits received iomeprol (Iomeron 300 mg/ml, Bracco s.p.a., Milan, Italy), a low osmolality (521 ± 24 mOsm/kg, 37 °C), low

viscosity (4.5 ± 0.4 mPa.s, 37 °C), nonionic iodinated contrast medium, at a dose of 1200 iodine mg/kg (12).

The purpose of this study was to evaluate the role of bone injection gun (BIG) assisted IO injection of contrast media in providing a safe and diagnostic urogram in rabbits.

Materials and Methods

This study was conducted on 6 normovolemic white adult New Zealand rabbits (mean weight, 1.7 kg; range, 1.5–2 kg). The rabbits were deemed normal prior to the study on the basis of physical examination, plasma biochemical profile, complete blood counts, urinalysis, and US of the kidneys and bladder.

All 6 rabbits were included in both the IV and IO studies during which induction of anesthesia with 80 mg/kg of ketamine was administered intramuscularly. All animals received a repeat dose of anesthetic equal to one-half of the original dose approximately 45 min into the experiment.

For IV injection, a 24-gauge 0.75 inch over-the-needle IV catheter was used to access the retroauricular vein. For the IO study, IO lines were established using an automatic device, a BIG (Wais Medical, Kress Corporation, USA), for the insertion of an 18-gauge trocar needle into the bone marrow. The depth of penetration for the trocar needle using BIG can be adjusted by unscrewing the sleeve from the cylindrical area chosen for the injection. For this study, to gain IO access to the distal-medial femur metaphysis, the depth of penetration was adjusted to 0.75 cm. The skin area was thoroughly cleaned with an antiseptic. The front part of the BIG was placed and in a perpendicular position to the site of injection held firmly. The safety pin was pulled out. The BIG was triggered by pressing the rear part against the 2 shoulder handles of

the housing and the sterile trocar needle was separated from its housing. The trocar stylet was manually pulled out from the needle and only the needle sheath remained in the bone. The needle was then connected to a standard IV infusion set. Correct needle placement was confirmed by observing spontaneous blood return from the needle, easy aspiration of blood, and easy infusion of fluid under gravity.

Radiographs were obtained 5, 10, and 15 min after IV injection. In order to ensure complete contrast medium removal from the blood, IO studies were performed 48 h later on the same rabbits with the same parameters (contrast medium amount, X-ray tube-table distance, X-ray doses). One hour after IO urographic examination, X-rays and MRIs of the BIG inserted bone segments were obtained from the Gülhane Military Medical Academy Department of Radiology. Two hours after IO injection, chest radiography and chest CT examinations were performed at the same department to exclude any fat embolus. X-ray, CT and MRI examinations were performed on all 6 rabbits.

Urograms obtained by the IV and IO routes were visually evaluated for quality (renal opacification, delineation of subgross renal anatomy, ureteral opacification, urinary bladder opacification and filling) by 2 radiologists who were unaware of the route of contrast administration.

Animals were observed until the effects of anesthesia had cleared and were further observed up to 48 h later in order to rule out any complications related to IV or IO urographic procedures. A complete blood count was performed 24 h after the intraosseous injection of contrast medium. The project received approval from the institutional review board.

Results

IO needle insertions were successful in all rabbits. Correct positionings in all rabbits were confirmed by aspiration of marrow content and easy infusion of fluid. The time required to establish the bone marrow infusion lines ranged between 45 and 70 s (median, 57 s). Contrast media IV infusion lasted for an average of 35 s (range, 30 to 40 s) with an average infusion rate of 0.20 ml/s, while IO infusion of the same amount of contrast media lasted for an average of 240 s (range, 210 to 270 s) with an infusion rate of approximately 0.03 ml/s.

IV and IO urograms are compared in the Table. Both IV and IO injections of contrast medium produced 5, 10 and 15 min urograms of satisfactory diagnostic quality in both groups. Although the 10 and 15 min urograms produced similar satisfactory opacification of the urinary system, the 5 min urograms in the IO sessions were clearer compared with those in the IV sessions (Figure 1a-d and Figure 2a-d).

Plain radiography (Figure 3) and MR (Figure 4a and b) images were taken in order to assess any bone or marrow injury, and did not display any adverse findings except for a bone defect at the site of BIG insertion. No sign of fat embolus was evident from chest radiography (Figure 5) or chest CT (Figure 6) in any of the rabbits.

The rabbits were followed up for a period of 48 h and no local or systemic complication was observed pertaining to the IO procedure, including immediate extravasations of contrast media.

Hematologic parameters before and after IO injection were similar for each rabbit and no circulating nucleated red blood cells, which can be an indicator of bone marrow injury, were identified.

Table. Evaluation of IV and IO urograms at 5, 10 and 15 min by 2 radiologists (IV: Intravenous, IO: Intraosseous, +: Bad, ++: Good, +++: Better)

Rabbits	5 min urogram				10 min urogram				15 min urogram			
	1st Radiologist		2nd Radiologist		1st Radiologist		2nd Radiologist		1st Radiologist		2nd Radiologist	
	IV	IO	IV	IO	IV	IO	IV	IO	IV	IO	IV	IO
1	++	+++	++	+++	+++	+++	+++	+++	+++	+++	+++	+++
2	++	+++	++	+++	+++	+++	+++	+++	+++	+++	+++	+++
3	++	+++	++	+++	+++	+++	+++	+++	+++	+++	+++	+++
4	++	+++	++	+++	+++	+++	+++	+++	+++	+++	+++	+++
5	++	+++	++	+++	+++	+++	+++	+++	+++	+++	+++	+++
6	++	+++	++	+++	+++	+++	+++	+++	+++	+++	+++	+++

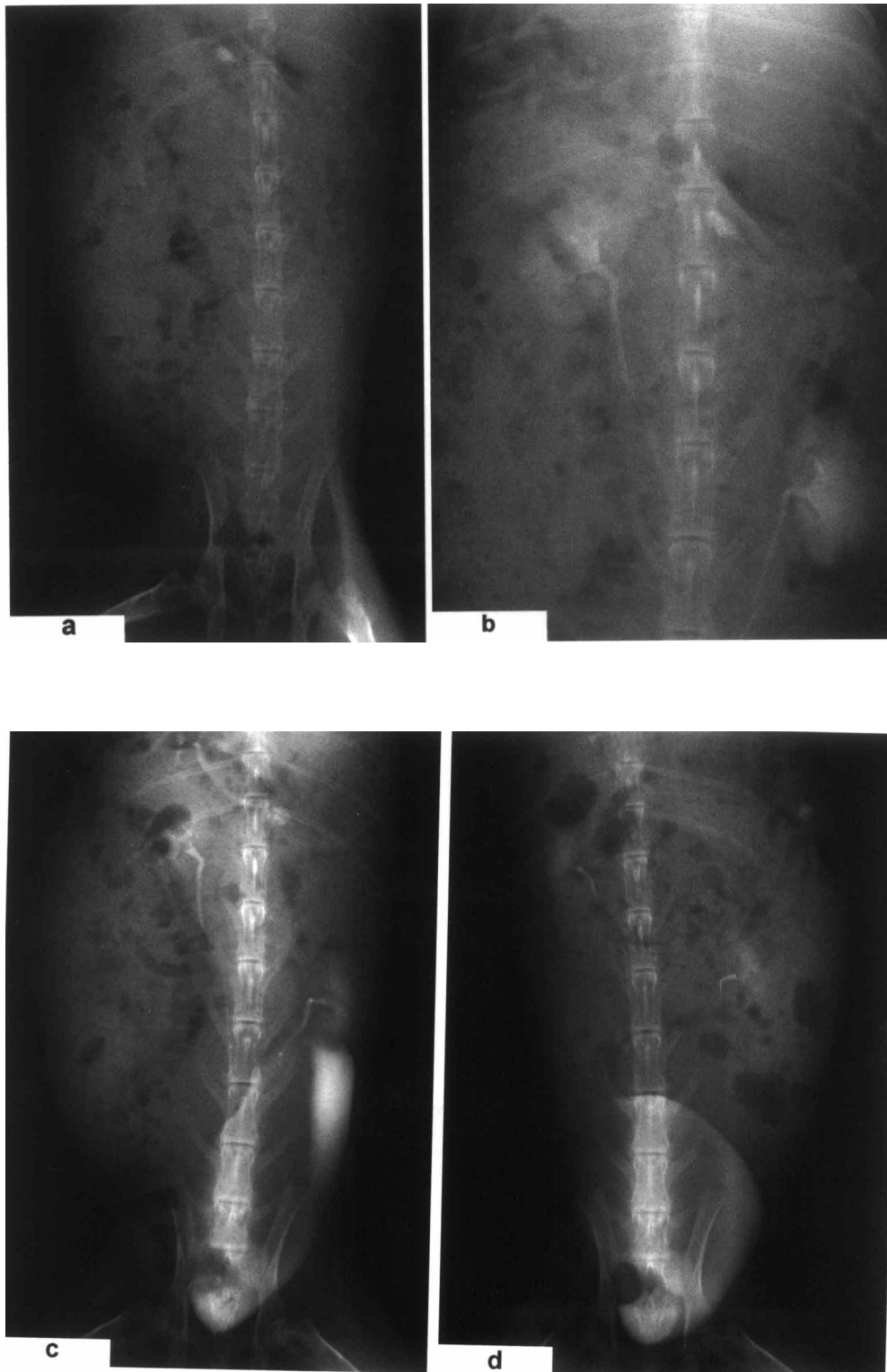


Figure 1. Intravenous urography (IVU) of a rabbit. a) Plain radiography, b) 5 min IVU, c) 10 min IVU, d) 15 min IVU.

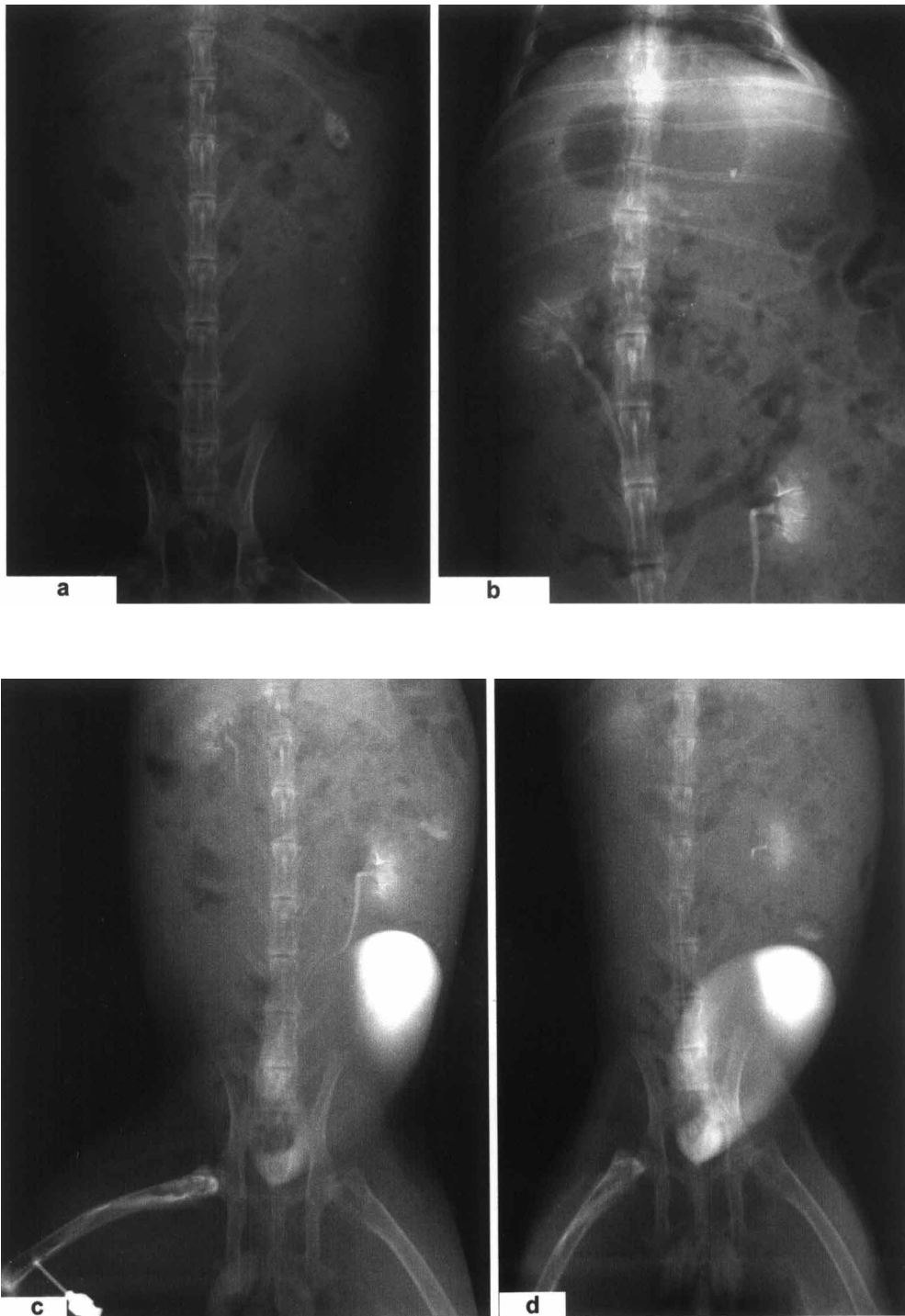


Figure 2. Intraosseous urography (IOU) of the rabbit in Figure 1. a) Plain radiography, b) 5 min IOU, c) 10 min IOU (BIG inserted to distal medial surface of right femur is also seen), d) 15 min IOU.

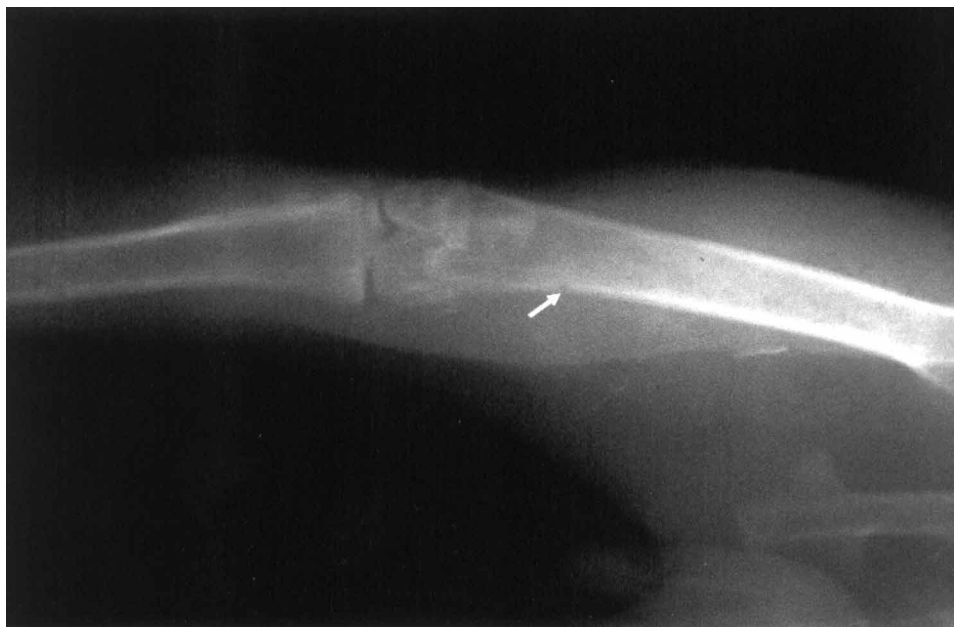

Figure 3. Plain radiography of the right femur. Tiny bone defect at the BIG insertion site is visualized (arrow).

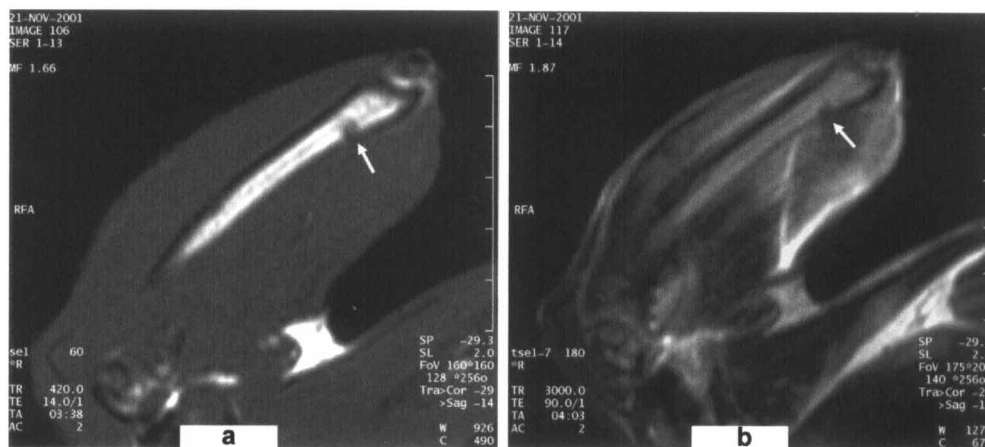

Figure 4. MRI of the right femur. a) T1 and b) T2 weighted spin echo longitudinal images do not reveal any abnormal bone or marrow findings, except for the hypointense site of BIG entrance (arrow).

Discussion

IO infusion is a technique that is used when traditional techniques are unsuccessful in reaching the vascular system, for reasons such as trauma, burns, hemodynamic collapse and sepsis (13). It is regaining popularity as a rapidly obtainable venous access route for the administration of fluids and drugs to infants and children who have hemodynamic collapse and in whom

conventional attempts to access the vascular system have been unsuccessful (10,11,14,15). The IO route for vascular access is based on the presence of non-collapsing veins that drain the medullary sinuses in the bone marrow. This vascular network empties into the central venous circulation via nutrient and emissary veins. This route is successful because the marrow cavity cannot collapse, allowing rapid access to the circulation despite

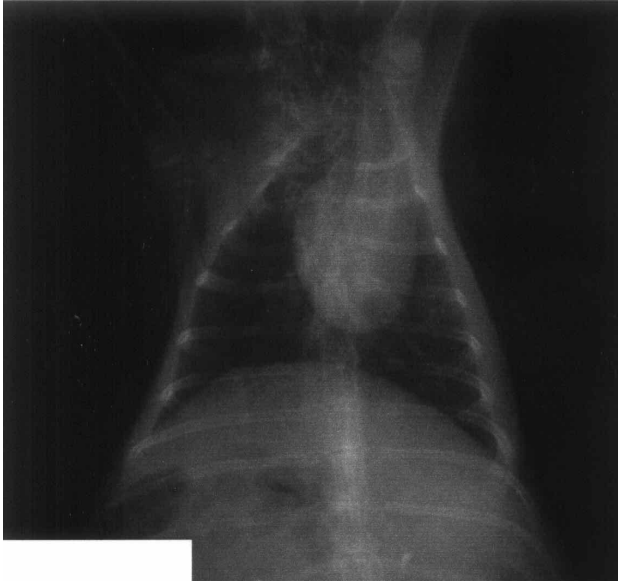

Figure 5. Chest radiography of the rabbit.

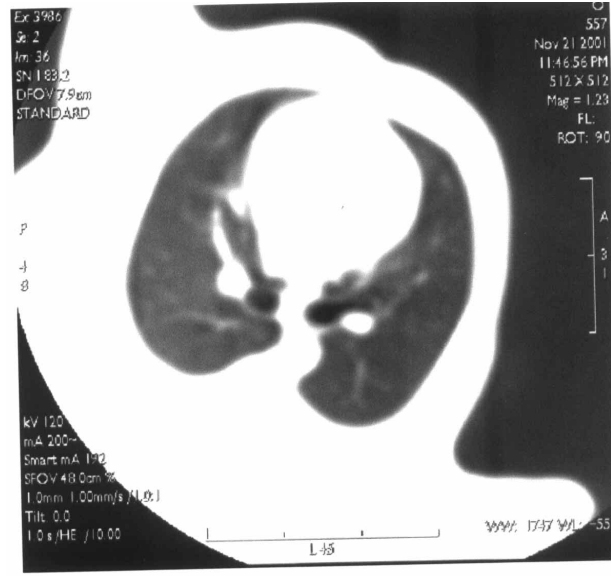

Figure 6. One sample slice of thoracic CT examination of the rabbit, at the hilar level.

profound hypovolemia (16). Contraindications of the IO route are osteogenesis imperfecta, osteoporosis, osteomyelitis, ipsilateral extremity fracture, previous IO cannulation attempts, and severe burns over the available superficial bones and local skin infections (17).

Multiple IO sites previously used or suggested have included the proximal tibia, medial malleolus, distal femur, proximal humerus, iliac crests, and sternum (18,19). Unless there is no alternative, truncal regions are not to be used because the sternal entrance may end up with large vessel perforation or osteomyelitis and iliac crests pose a potential subsequent problem of interference with a frequently used central access (19). We preferred to use the distal femur as an IO entrance site in this study, which enabled us to avoid gun injection complications in the relatively tiny bone structures of rabbits. Overall average duration, in the 6 rabbits, of accurate BIG insertion into the distal femur was 57 s.

The selected skin site is disinfected with povidone-iodine solution and, using surgical gloves, 2 to 4 ml of 1% lidocaine is infiltrated into the subcutaneous and periosteal layers in IO infusion clinical application. Since the impact insertion of a needle into a spongy bone is almost painless, local anesthesia of the skin and periosteum may not be necessary in the case of BIG

assistance. The injection of fluid (contrast media, drug etc.) causes pain (via intraosseal pain receptors) that disappears in 1 min. It is therefore recommended to withdraw 2 to 4 ml of bone marrow by aspiration and to inject 2 to 4 ml of 1% lidocaine slowly into the bone marrow (10,16,17).

In spite of the fact that the technique of IO access has been very well known for many years, many physicians are either unaware of its existence or avoid using it for various reasons. Avoidance behavior is related to a lack of experience and fear of complications. Reported complications of intraosseous infusion are unusual, but may include osteomyelitis, fat emboli, fracture at the intraosseous entry site, subperiosteal and subcutaneous infiltrations, sepsis, local cellulitis, and leakage from multiple puncture sites (10,14,17,19-25). The most common complication is the inability to enter the marrow cavity with subsequent extravasation of fluid into the subcutaneous tissues (16,19,21). However, this was mainly related to infusion volume and to poor needle insertion technique. Skin infection has been reported in 0.7% (5 out of 694) of cases, which is less than that reported with IV catheters (3.7%) (20). Osteomyelitis has been reported in 0.6% (27 out of 4270) of cases, with an increased risk if the needle is left in place for prolonged periods (20). Defects in bone growth after

infusions were not demonstrated in the animal models (26-28). However, it has been reported that IO needle placement creates a cortical defect visible on radiographs that usually resolves after 30 to 40 days (29).

All of the above complications could be avoided by using an automatic device that allows the fast and precise insertion of a trocar needle to a predetermined depth by trained personnel. The BIG's small trocar needle design permits a high velocity penetration through the bone cortex tightly into the spongy bone and provides the best stabilization of the needle at the access site, preventing leakage of fluids around it. In addition, since hypertonic solutions have been reported to be more harmful to epiphyseal plates than are isotonic solutions (25,26), choosing the lowest osmolality contrast media, as we did in this study, may help overcome this problem.

Central venous catheterization (CVC) or cut-down are 2 procedures in the event of failure of vascular access. In CVC, subclavian, internal-external jugular, femoral, basilic, and cephalic or brachiocephalic veins, and in cut-down saphenous (distal and proximal portions), antecubital, cephalic or external jugular veins are used. The necessary time for venous access varies with the experience of the physician in both techniques, which require skill and experience. A minimum of 5 min for CVC and a minimum of 10 min for cut-down are reasonable estimates. CVC is contraindicated in phlebitis, cellulitis, lymphedema and venous occlusive diseases. Cut-down should not be undertaken in cases of phlebitis, venous thrombosis or arterial insufficiency. Thromboembolism, phlebitis, and artery and nerve injuries are among the possible complications of in CVC and cut-down procedures. Pneumothorax, ventricular fibrillation, endocarditis and air embolism may also be observed in CVC. In addition, the accessed vein has to be ligated in a cut-down procedure (30,31). Taking all these factors into consideration, the bone insertion time of BIG in this study (less than 1 min), together with the absence of any complications, underlines the ease and safety of this IO urography technique.

The IO route of contrast injection was first experimented with in cadavers, dogs and rabbits (25,32-34). Visualization of the venous network via the IO route was possible in cadavers (32,33). In the study with dogs, an IO route of contrast media infusion with a rate of 8

ml/minute was found to be feasible; however, a contrast media amount exceeding 350 ml was reported to predispose to compartment syndrome (34). In a study with rabbits, IO urographic examination was performed utilizing 22-gauge 1.5 inch spinal needles with a dose of 600 mg iodine/kg body weight (diatrizoate and iopamidol). In that study, 3, 10 and 30 min urograms taken by the IV and IO routes were comparable; however, IO injections resulted in complications like bone fracture and osteochondrosis. It has been reported that the use of diatrizoate was associated with the development of osteochondrosis, but that the use of iopamidol was not (25).

We preferred iomeprol because of its lower osmolality and viscosity. Since we used an adjustable BIG with an impact insertion feature, no fracture-like complication or extravasation were observed, and hence the risk of osteochondrosis development related to iomeprol extravasation cannot be assessed. IO 5 min urograms had slightly better visualization of calices compared with IV 5 min urograms in this study. This may be postulated to be the result of the long lasting presence of contrast media in the circulation owing to a longer infusion time via the IO route (mean: 240 s total) compared to the IV route (mean: 35 s total). Neither the BIG nor contrast media (iomeprol) in this study caused any bone or bone marrow injury and the only sign of an osseous penetration was a tiny bone defect.

Bone marrow may respond to IO insults by liberating immature cells of the erythroid series into the circulation. While nucleated red blood cells may be present a few minutes after intraosseous injection, they cannot be detected in the systemic circulation 24 h later, suggesting a lack of sustained injury to the marrow (35,36). Circulating nucleated red blood cells were not evident in the blood samples taken 24 h after the IO injections in this study either.

In conclusion, BIG assistance for intraosseous urography (IOU) seems to be safe and diagnostic in rabbits. BIG assisted IO contrast injection for urography or CT of the urinary system may also be applicable as an alternative to the IV route in pediatric or adult human patients, when emergency urographic examination is required and the IO route is the only means of vascular access.

References

1. Friedland, G.W., Gross, D., Goris, M.L.: Intravenous urography (excretory urography) and excretory scintigraphy. p. 201-230. In: Friedland, G.W., Filly, R., Goris, M.L., Gross, D., Kempson, R.L., Korobkin, M., Thurber, B.D., Walter, J (eds.). *Uroradiology: An Integrated Approach*. Vol. 1, Churchill Livingstone, New York, 1983.
2. Jakse, G., Furtschegger, A., Egender, G.: Ultrasound in patients with blunt trauma managed by surgery. *J. Urol.*, 1987; 138: 21-23.
3. Mayor, B., Gudinchet, F., Wicky, S., Reinberg, O., Schnyder, P.: Imaging evaluating of blunt renal trauma in children: diagnostic accuracy of intravenous pyelography and ultrasonography. *Pediatr. Radiol.*, 1995; 25: 214-218.
4. Klein, L., Pollack, H.M.: Computed tomography and magnetic resonance imaging of the female lower urinary tract. *Radiol. Clin. North Am.*, 1992; 30: 843-860.
5. Medina, U., Lavery, R., Ross, S.E., Livingston, D.H.: Ureteral trauma: Preoperative studies neither predict injury nor prevent missed injuries. *J. Am. Coll. Surg.*, 1998; 186: 641-644.
6. Peterson, N.E., Pitts, J.C.: Penetrating injuries of the ureter. *J. Urol.*, 1981; 126: 587-590.
7. Tang, Y., Yamashita, Y., Namimoto, T., Abe, Y., Nishiharu, T., Sumi, S., Takahashi, M.: The value of MR urography that uses HASTE sequences to reveal urinary tract disorders. *Am. J. Roentgenol.*, 1996; 167: 1497-1502.
8. Calkins, M.D., Fitzgerald, G., Bently, TB., Burris D.: Intraosseous infusion devices: A comparison for potential use in special operations. *J. Trauma*, 2000; 48: 1068-1074.
9. Otto, C.M., Crowe, D.T.: Intraosseous resuscitation techniques and applications. p. 107-112. In: Kirk, R.W., Bonagura, J.D (eds.). *Current Veterinary Therapy*. 11th ed., WB Saunders Co., Philadelphia, 1992.
10. Hodge, D.: Intraosseous infusions: A review. *Pediatr. Emerg. Care*, 1985; 1: 215-218.
11. Kanter, R.K., Zimmerman, J.J., Strauss, R.H., Stoeckel, K.A.: Pediatric emergency intravenous access: Evaluation of a protocol. *Am. J. Dis. Child.*, 1986; 140: 132-134.
12. Dooley, M., Jarvis, B.: Iomeprol: A review of its use as a contrast medium. *Drugs.*, 2000; 59: 1169-1186.
13. Warren, D.W., Kisson, N., Sommerauer, J.F., Rieder, M.J.: Comparison of fluid infusion rates among peripheral intravenous and humerus, femur, malleolus, and tibial intraosseous sites in normovolemic and hypovolemic piglets. *Ann. Emerg. Med.*, 1993; 22: 183-186.
14. Burke, T., Kehl, D.A.: Intraosseous infusion in infants: Case report of a complication. *J. Bone Joint Surg.*, 1993; 75A: 428-429.
15. Gülanber, E.G., Or, E., Kaya, Ü., Öztürk, A.: Köpeklerde acil sıvı sađaltımlarında intraosseous (intramedullar) yolun kullanımı. *Vet. Cer. Derg.*, 1997; 3: 5-9.
16. Ryder, I.G., Munro, H.M., Doull, I.J.M.: Intraosseous infusion for resuscitation. *Arch. Dis. Child.*, 1991; 66: 1442-1443.
17. Fisher, D.H.: Intraosseous infection. *N. Engl. J. Med.*, 1990; 322: 1579-1581.
18. Tocantins, L.M., O'Neill, J.F.: Infusion of blood and other fluids into the circulation via the bone marrow. *Proc. Soc. Exp. Biol. Med.*, 1940; 45: 782-790.
19. Rogers, S.N., Benumal, J.L.: Intraosseous infusions. p. 339-343. In: Roberts, J.R., Hedges, J.R (eds.). *Clinical Procedures in Emergency Medicine*. WB Saunders Co., Philadelphia, 1985.
20. Rosetti, V.A., Thompson, B.M., Miller, J., Mateer, J.R., Aprahamian, C.: Intraosseous infusion: An alternative route of pediatric intravascular access. *Ann. Emerg. Med.*, 1985; 14: 885-888.
21. Smith, R.J., Keseg, D.P., Manley, L.K., Standeford, T.: Intraosseous infusions by prehospital personnel in critically ill pediatric patients. *Ann. Emerg. Med.*, 1988; 17: 491-495.
22. Heinild, S., Sondergaard, T., Tudvad, F.: Bone marrow infusion in childhood. Experiences from a thousand infusions. *J. Pediatr.*, 1947; 30: 400-411.
23. Tocantins, L.M., O'Neill, J.F.: Complication of intra-osseous therapy. *Ann. Surg.*, 1945; 122: 266-277.
24. Glaeser, P.W., Losek, J.D.: Emergency intraosseous infusions in children. *Am. J. Emerg. Med.*, 1986; 4: 34-36.
25. Porzio, P., Pharr, J.W., Allen, AL.: Excretory urography by intraosseous injection of contrast media in a rabbit model. *Vet. Radiol. Ultrasound.*, 2001; 42: 238-243.
26. Bielski, R.J., Basetti, G.S., Fideler, B., Tolo, V.T.: Intraosseous infusions: Effects on the immature physis. An experimental model in rabbits. *J. Pediatr. Orthop.*, 1993; 13: 511-515.
27. Bickman, K.R., Rega, P., Koltz, M., Guinness, M.: Analysis of growth plate abnormalities following intraosseous infusion through the proximal tibial epiphysis in pigs. *Ann. Emerg. Med.*, 1988; 17: 121-123.
28. Bickman KR, Rega P, Schoolfield L, Harkins K, Weisbrode SE, Reynolds G.: Investigation of bone developmental and histopathologic changes from intraosseous infusion. *Ann. Emerg. Med.*, 1996; 28: 430-435.
29. Spivey, W.H.: Intraosseous infusions. *J. Pediatr.*, 1987; 111: 639-643.
30. Parsa, M.H., Tabora, F., Al-Sawwaf, M.: Monitoring. p. 122-145. In: Shoemaker, W.C., Ayres, S., Grenvik, A., Holbrook, P.R., Thompson, W.L (eds.). *Textbook of Critical Care*. 2nd ed., WB Saunders Co., Philadelphia, 1992.
31. Shuck, J.M., Nearman, H.S.: Technical skills in patient care. p. 695-712. In: Davis, J.H., Drucker, R., Gamelli, R.L., Gann, D.S., Pruitt, B.A., Sheldon, G (eds.). *Clinical Surgery*. 1st ed., Mosby Co., St. Louis, 1987.

32. Steinbach, H.L., Jersen, F.: Osseous phlebography. *Surg. Gynecol. Obstet.*, 1957; 104: 215.
33. Litmanovitch, Y., Papo, J., Schorr, S.: Intraosseous phlebography. (Anatomical, topographic and hemodynamic problems). *Phlebptomies.*, 1977; 30: 277-299.
34. Gunal, I., Kose, N., Gurer, D.: Compartment syndrome after intraosseous infusion: An experimental study in dogs. *J. Pediatr. Surg.*, 1996; 31: 1491-1493.
35. Ros, S.P., McMannis, S.I., Kowal-Vern, A., Zeller, W.P., Hurley, R.M.: Effect of intraosseous saline infusion on hematologic parameters. *Ann. Emerg. Med.*, 1991; 20: 243-245.
36. Walker, D.: Peripheral blood smears. p. 271. In: Cowell, R.L., Tyler, R.D., Meinkoth, J.H (eds.). *Diagnostic Cytology and Hematology of the Dog and Cat*. Mosby Co., St. Louis, 1999.